Southern Medical Journal

JOURNAL OF THE SOUTHERN MEDICAL ASSOCIATION

VOL. 73 APRIL 1980 NO. 4

Published monthly by
THE SOUTHERN MEDICAL ASSOCIATION, Birmingham, Alabama, U.S.A. 35256

Midtrimester Dilatation and Evacuation Abortion

DAVID A GRIMES, MD, and JAROSLAV F. HULKA, MD,† Chapel Hill, NC

ABSTRACT: At a university referral hospital where midtrimester abortions are performed by prostaglandin $F_{2\alpha}$ instillation, interest in reports of lower morbidity with dilatation and evacuation (D&E) led to the development of a D&E technic for outpatient use at 13 to 16 weeks' gestation. Of the first 19 women offered this method instead of the standard hospitalization and prostaglandin instillation, all 19 accepted. The D&E technic for pregnancies ≥15 weeks' gestation included overnight laminaria treatment, intracervical block using lidocaine with epinephrine, and Bierer forceps for extraction. There were no complications. This favorable initial experience indicates the need for evaluation of the comparative safety of midtrimester abortion by D&E versus instillation of prostaglandin $F_{2\alpha}$.

MIDTRIMESTER ABORTIONS are usually referred to a small number of hospitals and clinics providing this special service. At these institutions, the most common abortion technic entails hospitalization and intra-amniotic instillation of hypertonic solutions, prostaglandin $F_{2\alpha}$, or a combination of these agents. Recent reports,[1-5] however, have described lower morbidity and less pain with dilatation and evacuation (D&E) for midtrimester abortions. Although D&E has emerged as the second most frequent method of performing abortions at ≥13 menstrual weeks in the United States,[6] and although the traditional 12-week limit for D&E lacks a solid clinical or scientific base,[7] few university centers[8,9] perform midtrimester D&E abortions or offer training in this method.

The North Carolina Memorial Hospital at Chapel Hill is a state referral hospital associated with the University of North Carolina School of Medicine, to which approximately 300 candidates for midtrimester abortion are referred annually for instillation abortions. Interest in evaluating the usefulness of the D&E method on such a service led to discussing technical details of the procedure with several practitioners and visiting two of them to observe their technics. The procedure for midtrimester D&E thus developed will be described in this report, together with our initial clinical experience.

TECHNIC

Selection of Patients. Advice by experienced practitioners led to limiting the initial trial to patients 13 to 16 weeks beyond their last menstrual period. No age or parity restrictions were used. During the first month of the evaluation, 19 such women were referred to this service. Social workers and nurses counseled the women about the available methods. Each woman was offered a choice of the standard method of waiting until 16 weeks' gestation for admission for prostaglandin $F_{2\alpha}$ instillation, or performance within one week of outpatient D&E as an experimental procedure. All chose D&E.

Technic. One of us (D.A.G.) performed each abortion. For pregnancies at 13 to 14 weeks' gestation, cervical dilatation with Pratt dilators to 39 or 41 French required little effort. Evacuation was accomplished primarily with a 12 mm straight suction cannula.* The surgeon rotated the tip of the cannula only in the lower portion of the uterus just beyond the internal os, minimizing the risk of perforation. As the uterus was evacuated, its contraction would bring the intrauterine contents to the cannula opening, and the bulk of tissue was removed by suction aspiration alone. The surgeon used standard sponge forceps to complete the evacuation, again reaching only into the area of the uterus just above the internal os and relying on uterine contraction to bring intrauterine contents to the sponge forceps rather than reaching deeply into the cavity. Gentle sharp curettage confirmed the completeness of evacuation.

For pregnancies ≥15 menstrual weeks, the size of the fetal parts to be removed required the use of larger ovum forceps and greater dilatation. Because dilatation to a large diameter over the short period of surgery may be associated with cervical laceration or other trauma,[10] gradual cervical dilatation with laminaria overnight was chosen.

†From the Department of Obstetrics and Gynecology, University of North Carolina School of Medicine, Chapel Hill, NC 27514.
Reprint request to The Family Planning Evaluation Division, Bureau of Epidemiology, Center for Disease Control, Atlanta, Ga 30333 (Dr. Grimes).

*Berkeley Bio-Engineering, Inc., Berkeley, Calif 94710.

The women were seen in a hospital treatment room the evening before a scheduled D&E. After reviewing the purpose of the laminaria with each woman, the surgeon inserted a sterile Graves speculum and cleansed the vagina and cervix with povidone-iodine solution. A single-tooth tenaculum was placed on the anterior cervical lip, and 5 ml of 1% lidocaine was injected at 3, 5, 7, and 9 o'clock, the surgeon's customary paracervical block technic. After a two-minute wait, laminaria** (without their plastic collars) were inserted into the cervix until the distal end with the string was flush with the external os, assuring that the tapered end had traversed the internal os. Each laminaria was moistened with povidone-iodine solution for lubrication, antisepsis, and acceleration of expansion. Starting with thick laminaria, we placed as many as would fit comfortably, continuing with medium-thick laminaria until the fit was snug or the patient experienced pain. The surgeon then left two 4 x 4 gauze sponges in the vagina as packing (Fig 1). The total number of laminaria used ranged from five to seven, with a mean of 5.5.

Because nearly all our patients lived considerable distances from the hospital, they stayed overnight in a nearby motel unit. Most had a friend or relative to spend the night with them and drive them home after the abortion.

The next morning, patients and escorts reported to the outpaitent surgery lounge[11] in the hospital. An IV was started in the operating room, intravenous diazepam or fentanyl was given as needed, and the patient was placed in the dorsal lithotomy position. The surgeon removed the laminaria (Fig 2), scrubbed the vagina and perineum, and sat with an instrument tray in his lap and an instrument table and suction machine to his right.

Each woman received intracervical anesthesia according to the method of Finks.[12] After inserting a Graves speculum and placing a tenaculum on the anterior cervix, the surgeon injected tracts of approximately 2.5 ml of 1% lidocaine with epinephrine 1:100,000 into the cervix at eight compass points, thus using a total of 200 mg of lidocaine. Each injection began at the full depth of a 1.5 inch 22-gauge needle attached to the syringe. This placed anesthetic throughout the full thickness of the cervix as well as into portions of the lower uterus. Several minutes were allowed for absorption and vasoconstriction before inserting instruments into the uterus. Special instruments required for midtrimester evacuation included a Bierer ovum forceps* and a set of four large Pratt dilators‡ ranging from size 45 to 59 French (Figs 3 and 4). Total cost for these instruments was less than $200.

Cervical dilatation required little effort, thus minimizing the risk of cervical or uterine trauma. Pratt dilators up to No. 59F would pass without resistance after laminaria had been removed. If the cervix would not accommodate a No. 55F Pratt dilator (dilatation required for insertion of the Bierer forceps), the cervix was dilated to at least this size.

Evacuation began by draining the amniotic fluid with a 12 mm straight suction cannula and aspirating as much tissue as possible. The tip of the suction cannula was rotated only in the lower portion of the uterus.

The uterine contents were primarily emptied with the Bierer forceps, which were inserted into the lower portion of the uterus; the jaws were opened, then closed and withdrawn. As tissue was recovered, the surgeon placed it on the lap tray for inspection. The suction cannula was used as a traction device to draw tissue into the lower portion of the uterus. Alternating between suction and forceps extraction, the process was continued until all major fetal parts had been identified. Suction and gentle sharp curettage then completed the evacuation. Since bleeding was usually negligible at this point, oxytocics were not used routinely. Oxytocics were not used during the evacuation for fear of "trapping" the calvarium. Total operat-

**Dilateria, Milex Products, Chicago, Ill 60631.

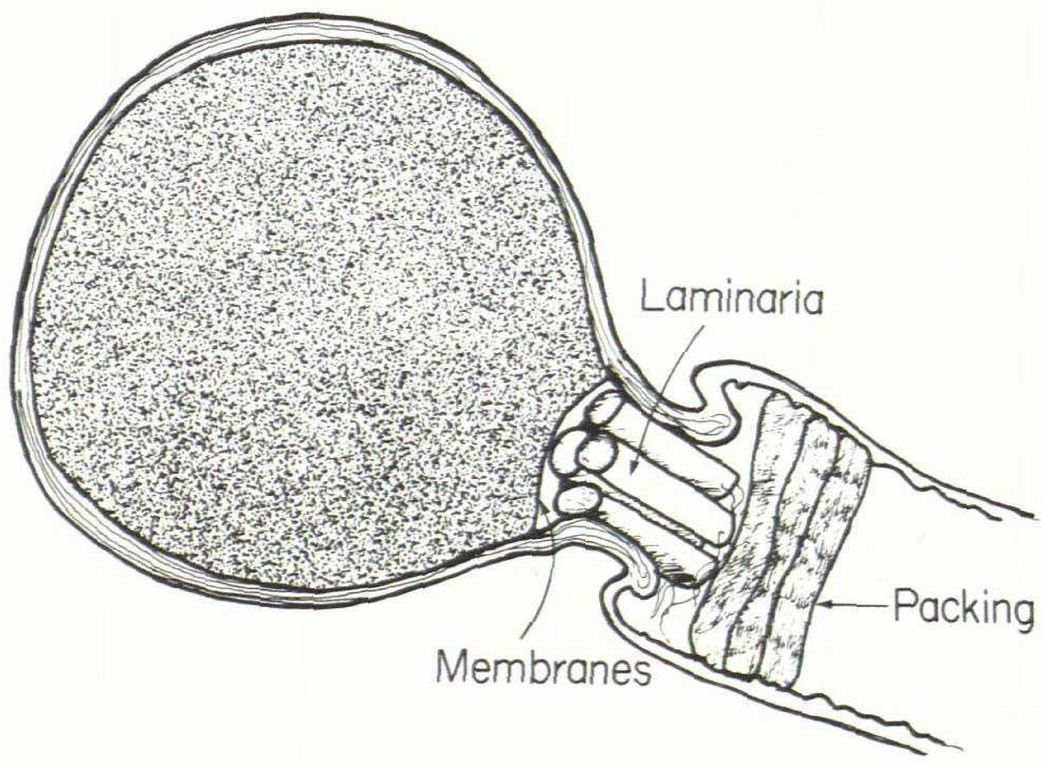

FIGURE 1. Position of laminaria in cervical canal.

‡Rocket of London, Branford, Conn 06405.

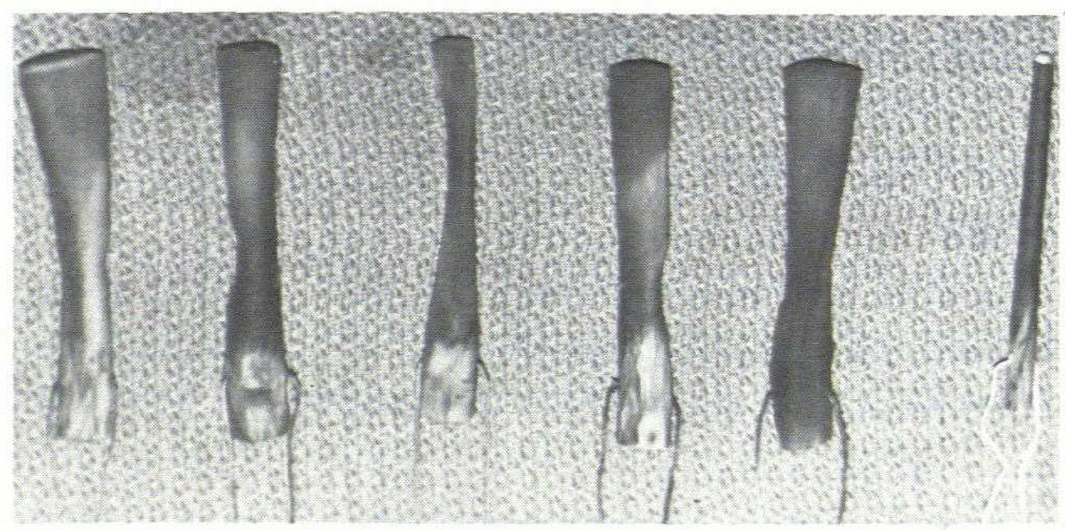

FIGURE 2. Removed laminaria (four thick and one medium-thick) compared to unused thick laminaria. Areas of constriction ("dumbbell" shape) identify level of internal os.

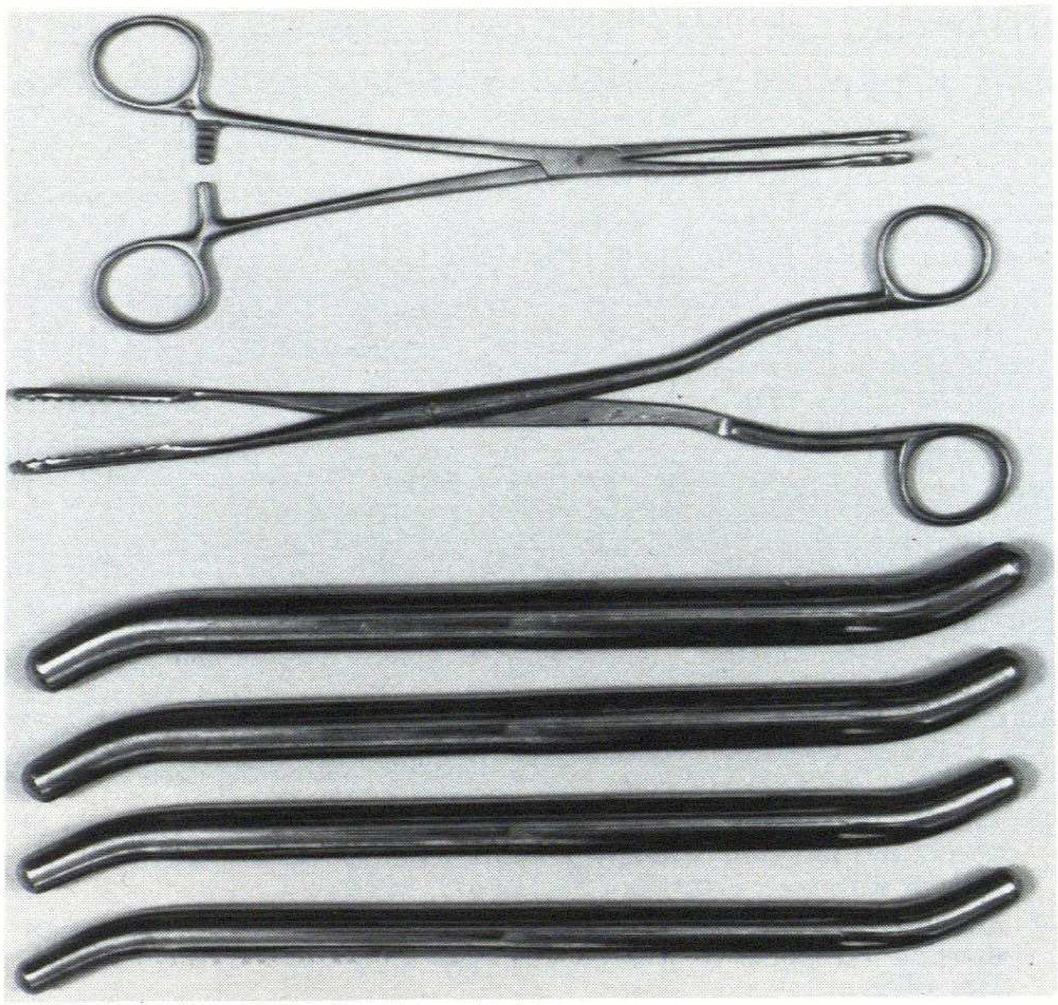

FIGURE 3. Bierer ovum forceps and large Pratt dilators. Standard sponge forceps is shown for comparison.

ing time ranged from ten to 25 minutes, with estimated blood loss averaging less than 200 ml.

After operation, the women spent approximately 30 minutes in the recovery room, thereafter returning to the outpatient surgery lounge where they had snacks and visited with family or friends. Each woman received a thermometer after the abortion with instructions to take her temperature twice daily for five days and to report any elevation. The surgeons' telephone numbers were given, and she was urged to call if problems developed. Discharge from the hospital outpatient lounge occurred about 90 minutes after leaving the operating room.

RESULTS

In the first month of this program, 19 women had midtrimester D&E abortions as outpatients. Their mean age was 20.3 years, and mean gravidity 1.9. Fetal foot lengths were compared to the mean lengths reported by Streeter[13] to verify the gestational age of each pregnancy estimated to be ≥14 menstrual weeks. In these 19 women, gestational ages ranged from 13 to 18 weeks: 13 weeks (five), 14 (four), 15 (one), 16 (three), 17 (four), and 18 (two). The mean gestational age was 15.2 weeks.

No immediate complications occurred. The women reported that the laminaria caused negligible to moderate menstrual-type cramping overnight and reported minimal discomfort during the operation. Each woman was scheduled for a follow-up visit in two weeks. If a woman failed to keep her appointment, clinic personnel made three attempts to reach each woman by phone or mail. Although nearly all the women resided out of town, follow-up information was obtained on 11 (58%). No delayed or late complications have been reported.

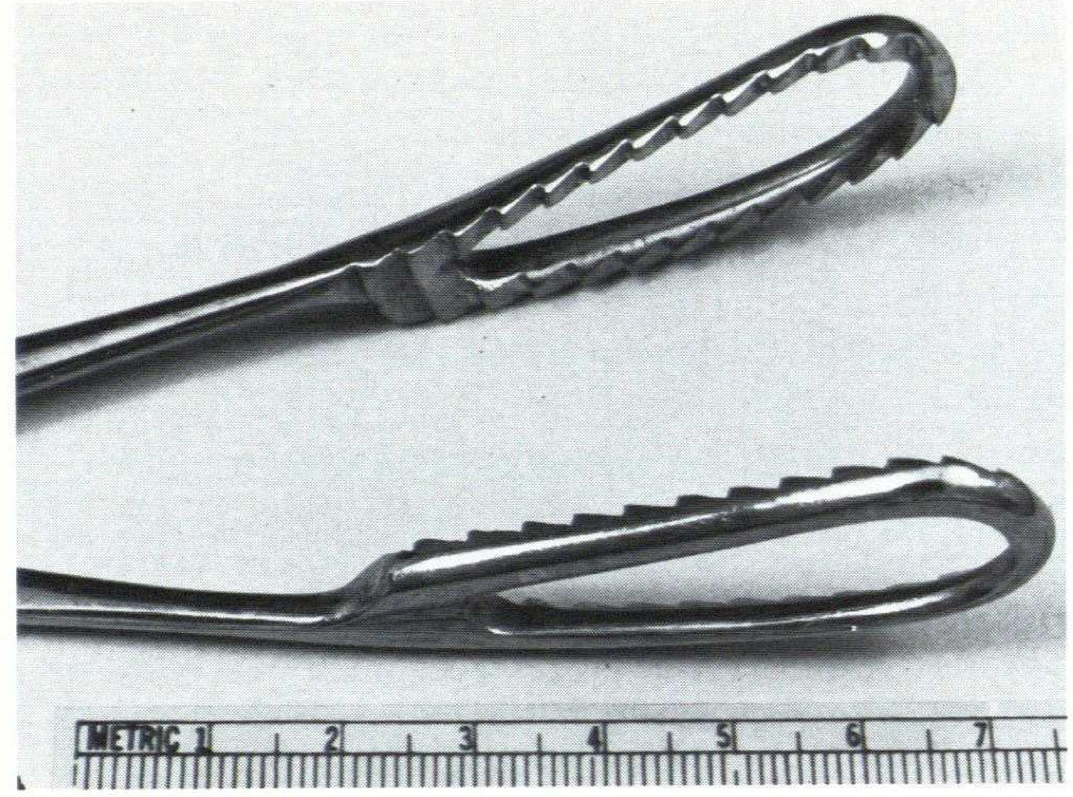

FIGURE 4. Designed for midtrimester evacuation, Bierer forceps has larger grasping area (20 mm at widest point) and larger reverse serrations than standard ovum forceps to grasp and retain larger fetal parts, such as calvarium.

DISCUSSION

This preliminary experience suggests that midtrimester D&E abortions can be done comfortably and safely with the woman under local anesthesia in an outpatient setting. The acceptance by all 19 women of this experimental method attests to its psychologic appeal as compared to induction of labor and expulsion of the fetus in bed.[9,14] The initial cost of equipment was low, and we easily integrated these women into an established outpatient surgery program.

Critics of midtrimester D&E abortions have asserted that extraordinary skills are required.[15] On the contrary, midtrimester D&E appears technically simpler than vaginal hysterectomy, an operation all gynecologists are trained to do. Unless teaching institutions begin to use and teach midtrimester D&E, the lack of operator skill now alledged may become a self-fulfilling prophecy. This report demonstrates that low morbidity rates can be achieved even without prior experience with the method.

As with other operations, hemostasis and adequate exposure are critical. Although not yet subjected to rigorous study, the intracervical block with local anesthetic and epinephrine has resulted in minimal intraoperative bleeding in extensive experience in the United States[4] and overseas.[12,16] We found that the cervix becomes pale within minutes of injection of the vasoconstrictor and by the end of the abortion the cervix is dusky. Uptake of vasoconstrictor into the uterus may be responsible for the effective hemostasis.[12]

As has been documented in later pregnancies, overnight treatment with laminaria not only dilates the cervix but also significantly increases cervical ripeness.[17] If additional dilatation is required after removal of the laminaria, only minimal force is necessary. In the group receiving laminaria, premature rupture of membranes did not occur. Cervical dilata-

tion with Pratt dilators at 13 to 14 weeks' gestation required little force as well, consistent with the finding that the force required to dilate the cervix decreases with advancing gestational age.[18]

The technic of midtrimester D&E has had two other important applications in this referral hospital: evacuation of failed instillation abortions[19] and treatment of septic incomplete abortions. With failed instillation abortions, if adequate dilatation has not been achieved by labor, we used overnight laminaria treatment before evacuation. In the management of septic incomplete abortions referred to our hospital, the large Pratt dilators and Bierer ovum forceps have greatly extended our gestational age range for vaginal evacuation, so that many seriously ill women may be spared hysterotomy, hysterectomy, or attempts to empty the uterus with oxytocin infusions.[20] In a recent case, a woman was brought to the hospital in septic shock at 17 weeks' gestation after her membranes had ruptured two days before. Within two hours after admission, her uterus was evacuated under local anesthesia, and her subsequent recovery was uneventful.

In conclusion, outpatient midtrimester D&E presents an attractive alternative to instillation abortions. Advantages include excellent acceptance by women, avoidance of delays until ≥16 weeks for amniocentesis, minimal discomfort, and low morbidity. On the other hand, this technic requires more technical facility than instillation abortions, and it shifts much of the emotional burden of midtrimester abortion from the woman and nursing staff to the surgeon.[9,14] This favorable early experience indicates the need for evaluation of the comparative safety of midtrimester abortion by D&E versus instillation of prostaglandin; accordingly, we have initiated a randomized clinical trial comparing midtrimester abortion by these two technics.

References

1. Hodari AA, Peralta J, Quiroga PJ, et al: Dilatation and curettage for second trimester abortions. *Am J Obstet Gynecol* 127:850-854, 1977
2. Hern WM, Oakes AG: Multiple laminaria treatment in early midtrimester outpatient suction abortion: a preliminary report. *Adv Plann Parent* 12:93-97, 1977
3. Grimes DA, Schulz, KF, Cates W Jr, et al: Midtrimester abortion by dilatation and evacuation . a safe and practical alternative. *N Engl J Med* 296:1141-1145, 1977
4. Barr MM: Mid-trimester abortions: 12 to 20 weeks by dilatation and evacuation method under local anesthesia. *Adv Plann Parent* 13:16-20, 1978
5. Hanson MS: Abortion in teenagers. *Clin Obstet Gynecol* 21:1175-1190, 1978
6. Center for Disease Control, *Abortion Surveillance 1976*, August 1978
7. Grimes DA, Cates W Jr: Gestational age limit of 12 weeks for abortion by curettage. *Am J Obstet Gynecol* 132:207-210, 1978
8. Stubblefield PG, Albrecht BH, Koos B, et al: A randomized study of 12-mm and 15.9-mm cannulas in midtrimester abortion by laminaria and vacuum curettage. *Fertil Steril* 29:512-517, 1978
9. Kaltreider NB, Goldsmith S, Margolis AJ: The impact of midtrimester abortion techniques on patients and staff. *Am J Obstet Gynecol* 135:235-238, 1979
10. Hulka JF, Higgins G: Tears of the internal cervical os during dilatation for routine curettage. *Am J Obstet Gynecol* 82:913-918, 1961
11. Patterson JF Jr, Bechtoldt AA, Levin KJ: Ambulatory surgery in a university setting. *JAMA* 235:266-268, 1976
12. Finks AA: Mid-trimester abortion. *Lancet* 1:263-264, 1973
13. Streeter GL: Weight, sitting height, head size, foot length, and menstrual age of the human embryo. *Contrib Embryol* 11:145-159, 1920
14. Rooks JB, Cates W Jr: Emotional impact of D&E vs. instillation. *Fam Plann Perspect* 9:276-278, 1977
15. Flowers CE: Discussion. *Am J Obstet Gynecol* 131:14, 1978
16. Van Den Bergh AS: Abortion procured in the second trimester of pregnancy. *Med Contact* 29:1555-1560, 1974
17. Cross WG, Pitkin RM: Laminaria as an adjunct in induction of labor. *Obstet Gynecol* 51:606-608, 1978
18. Hulka JF, Lefler HT Jr, Angelone A, et al: A new electronic force monitor to measure factors influencing cervical dilatation for vacuum curettage. *Am J Obstet Gynecol* 120:166-173, 1974
19. Burkman RT, Atienza MF, King TM, et al: The management of midtrimester abortion failures by vaginal evacuation. *Obstet Gynecol* 49:233-235, 1977
20. Andriole VT: Bacterial infections. *Medical Complications During Pregnancy*. Burrow GN, Ferris TF (eds). Philadelphia, W. B. Saunders Co., 1975, pp 382-413



"The exclusive purpose of this Association shall be to develop and foster scientific medicine."